



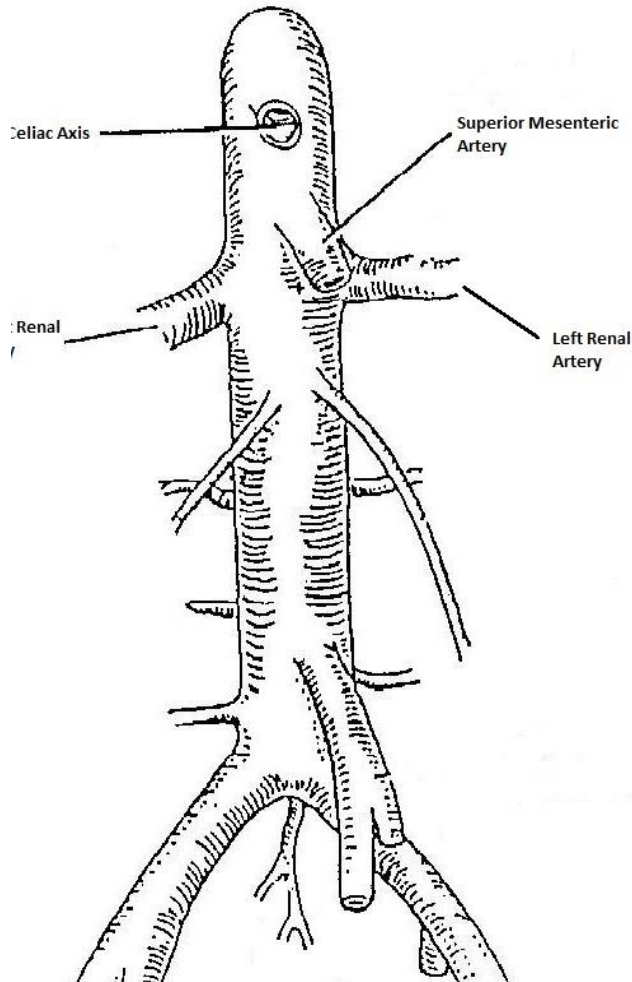
CARDIORISK AAA SCREENING

Patient Name: WHEATON, CLARICE Date: 03-26-2025

DOB: 10/26/1953 Sex: F

Referring Provider: AMY BASS

Vascular Technician: TIFANY DOUGLAS



Aorta Prox

1.5 cm Trans X 1.5 cm AP

Aorta Mid

1.5 cm Trans X 1.5 cm AP

Aorta Distal

1.6 cm Trans X 1.6 cm AP

Comments: No Abdominal Aortic Dilatation / Aneurysm was identified in the submitted images. A small amount of calcified plaque was identified in the Abdominal Aorta. A small amount of non-calcified plaque was visualized in the Abdominal Aorta.



